



Head and neck pain

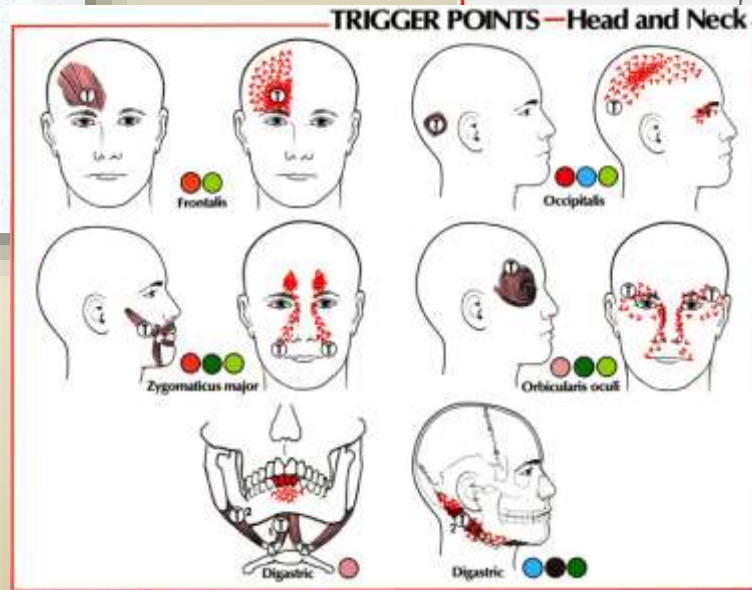
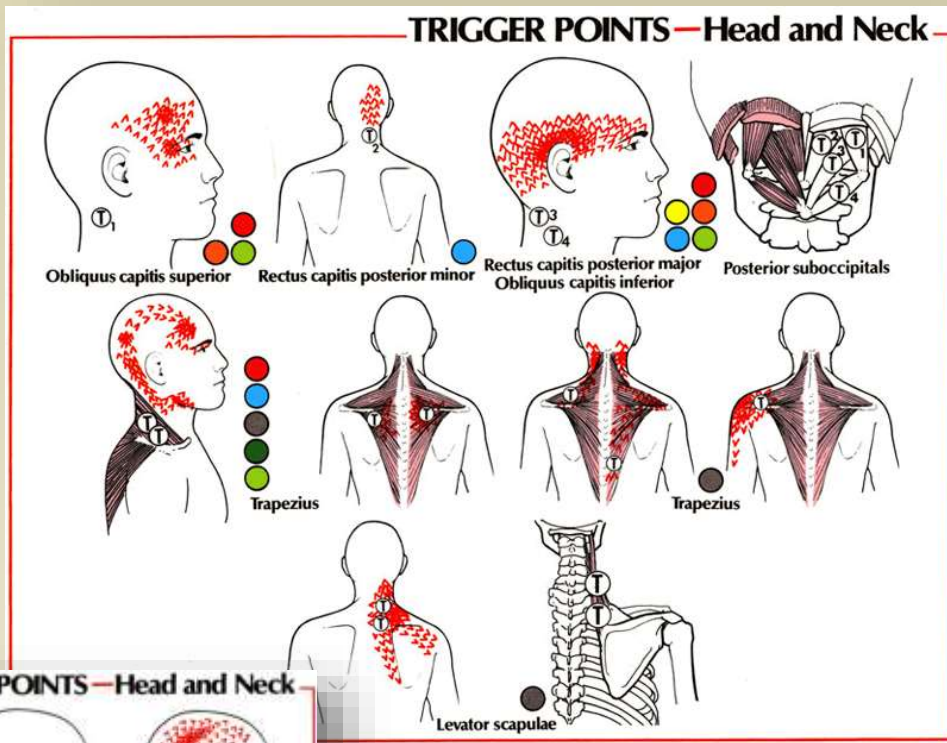
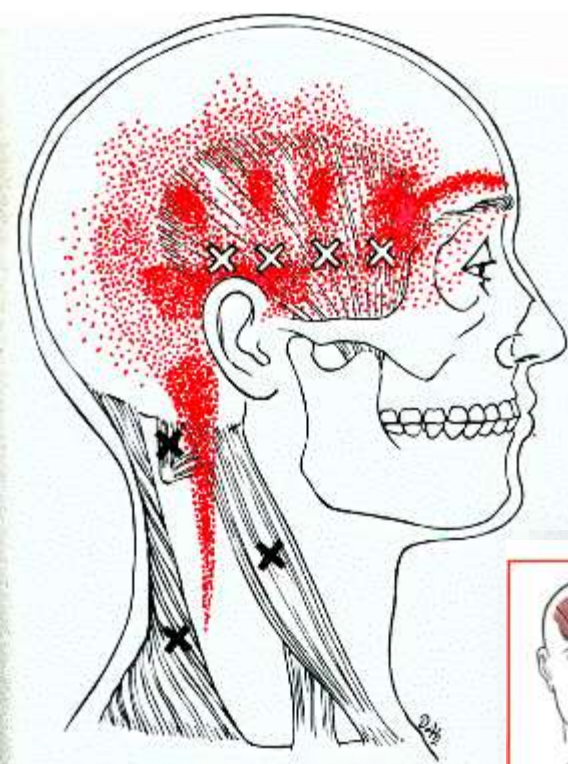
Trapezius

John Kent, BSc, MD

Rambam School of Pain Medicine, Haifa Israel

Founder, Israeli Society of Musculoskeletal Medicine

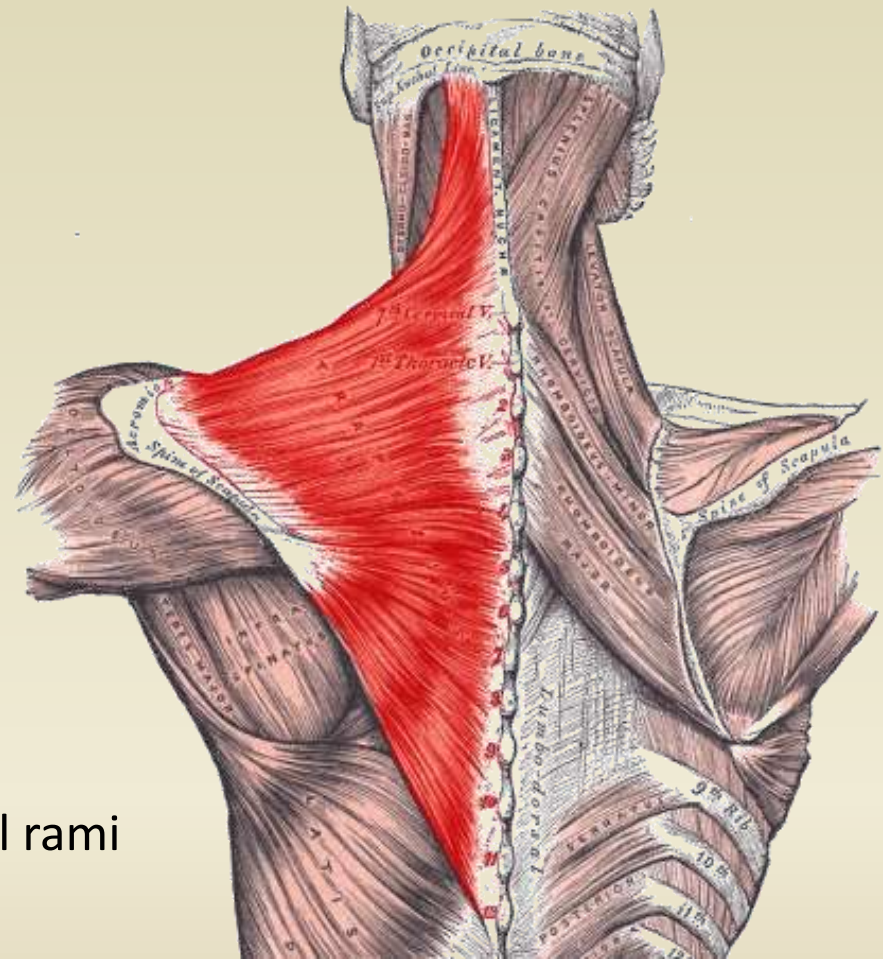
Muscle Pain Maps



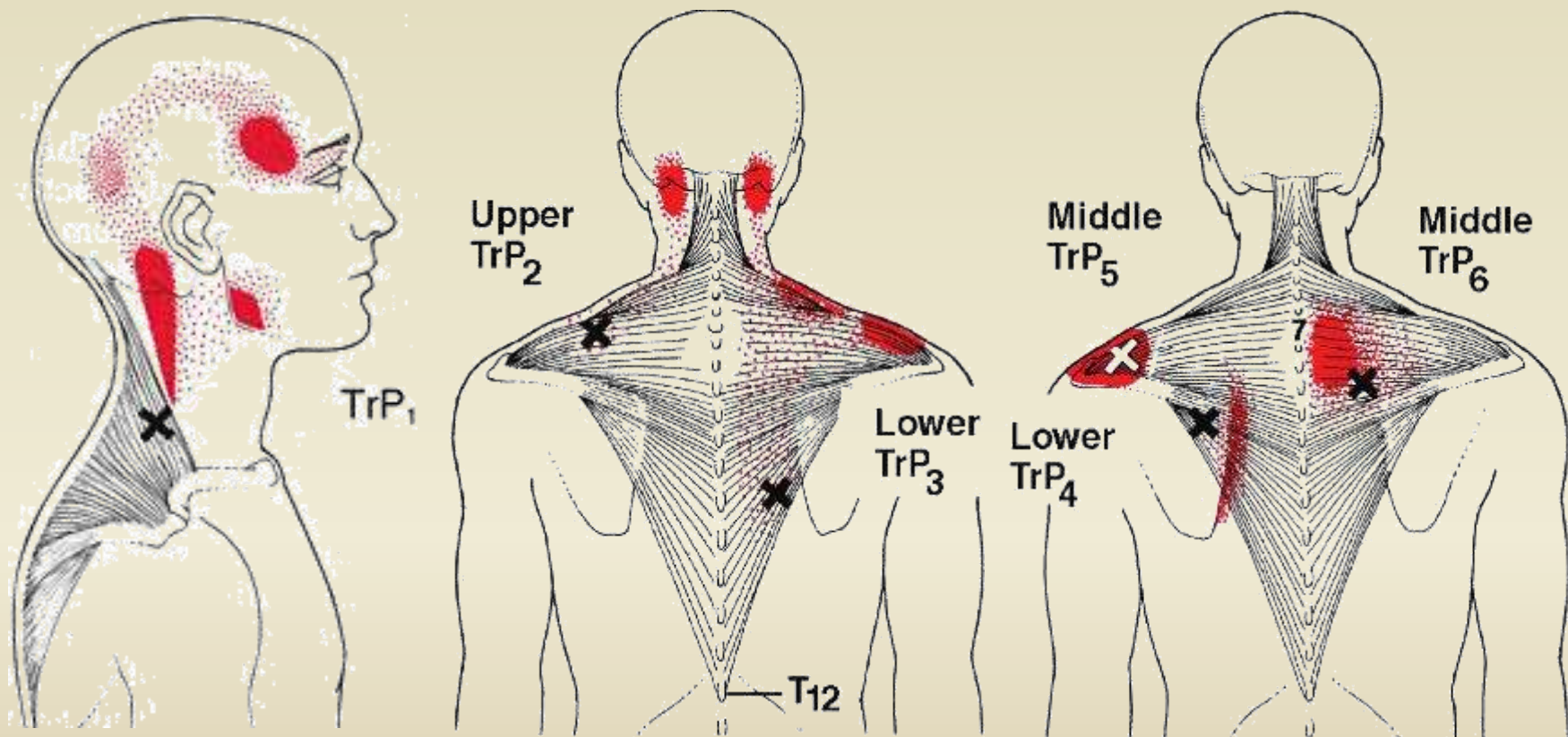
The most common pain syndrome: Trapezius

Innervation

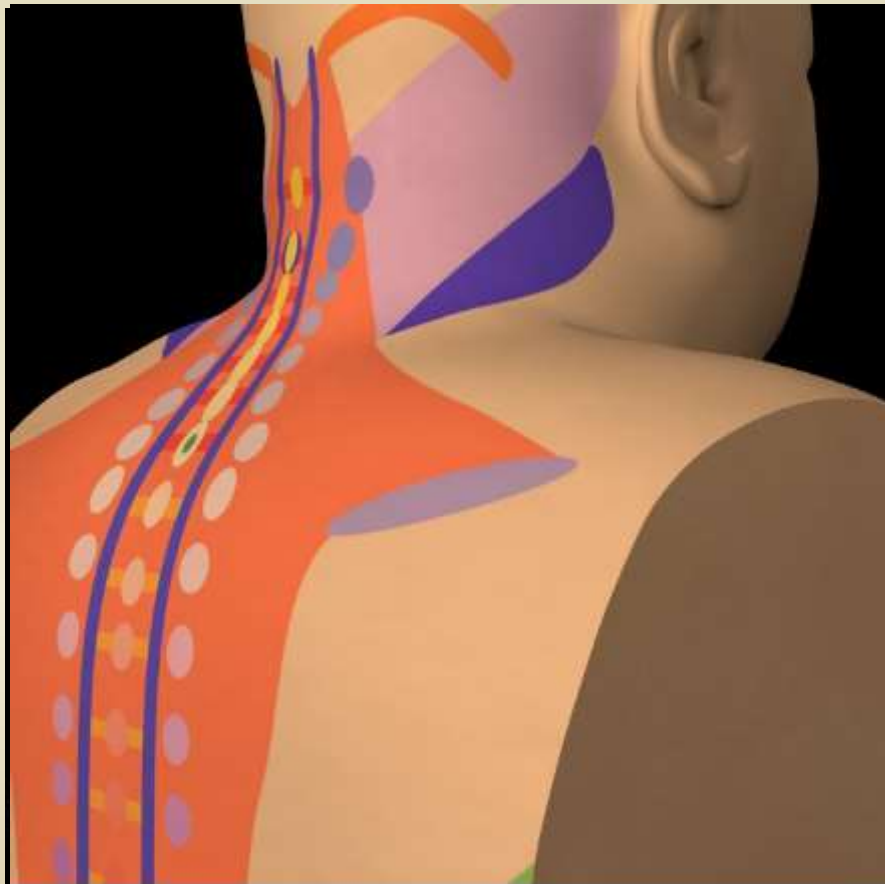- **Motor:**
 - spinal accessory nerve (CN XI)
- **Sensory** (pain, proprioception):
 - ventral rami of C3 and C4
- **muscle of the upper limb**
 - **trapezius is not innervated** by dorsal rami
(*despite it being superficial on the back*)



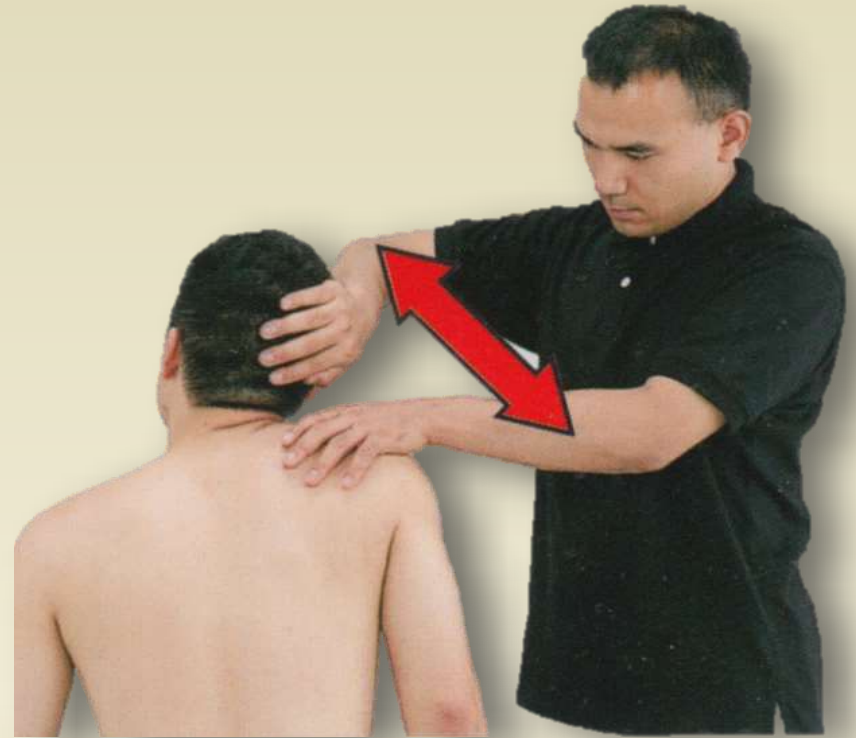The most common pain syndrome: Trapezius



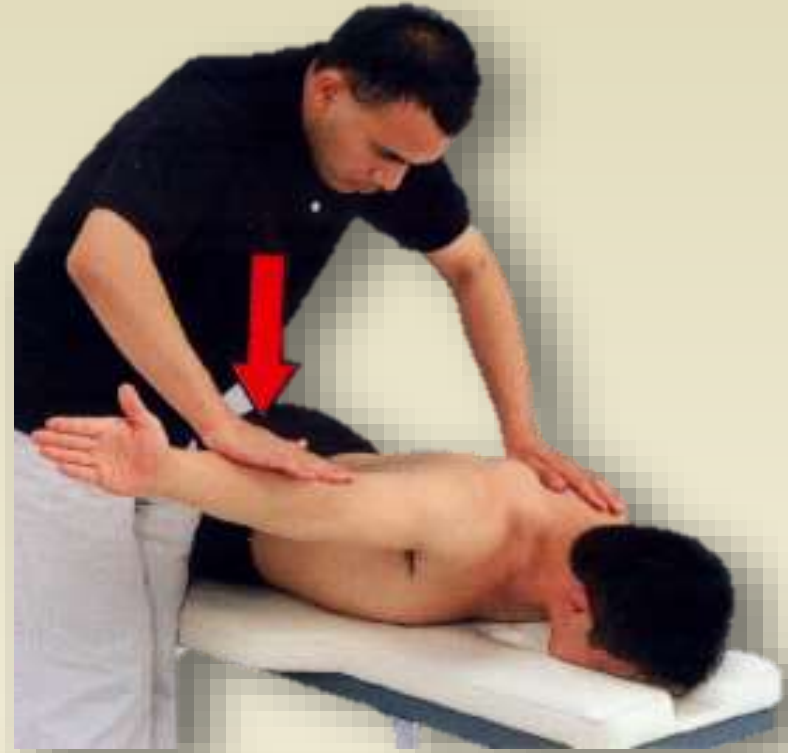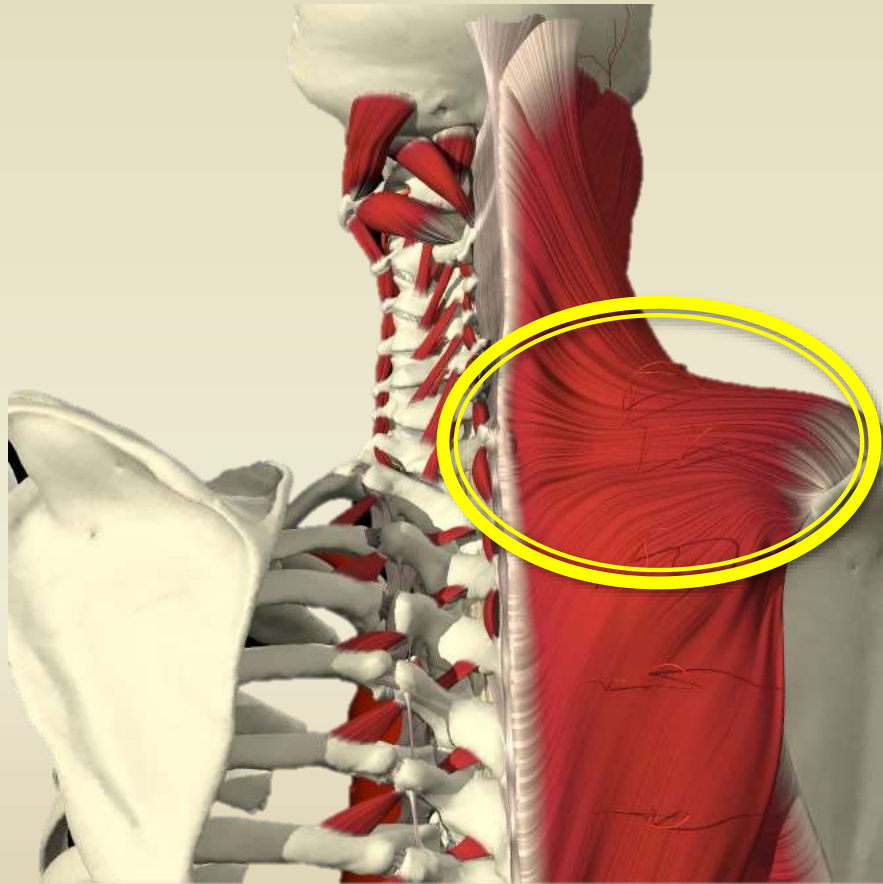
Upper Trapezius Examination



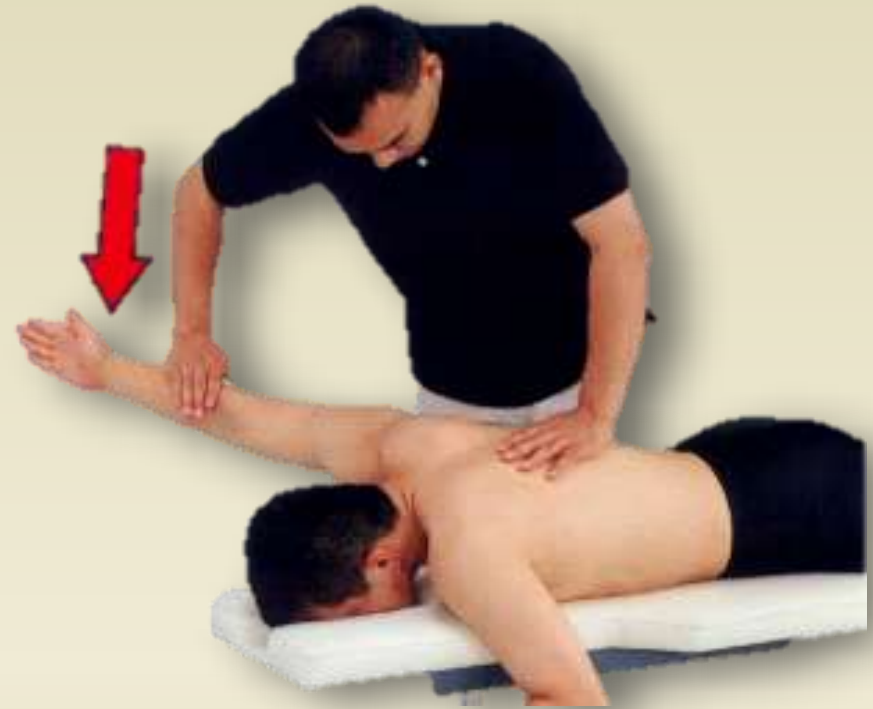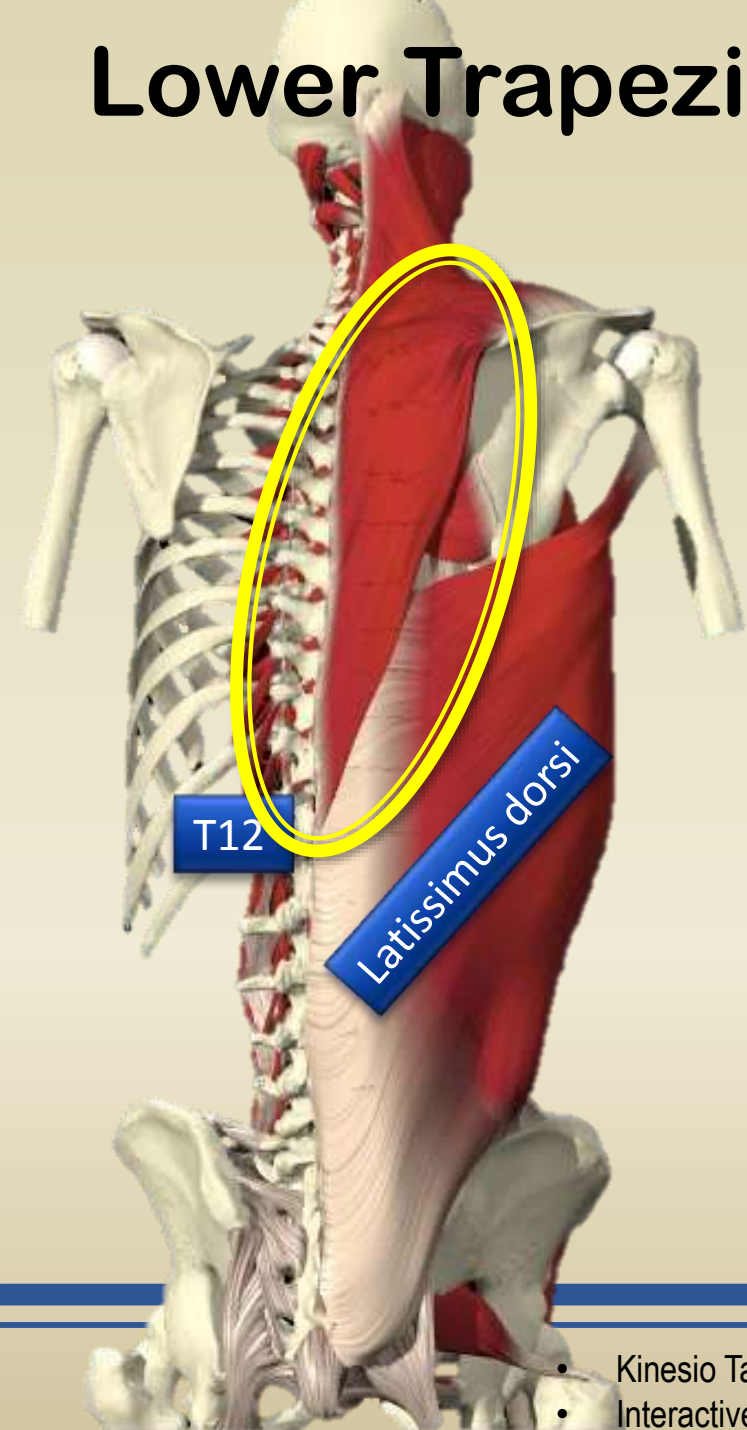
© 2003 Primal Pictures Ltd.



Middle Trapezius Examination



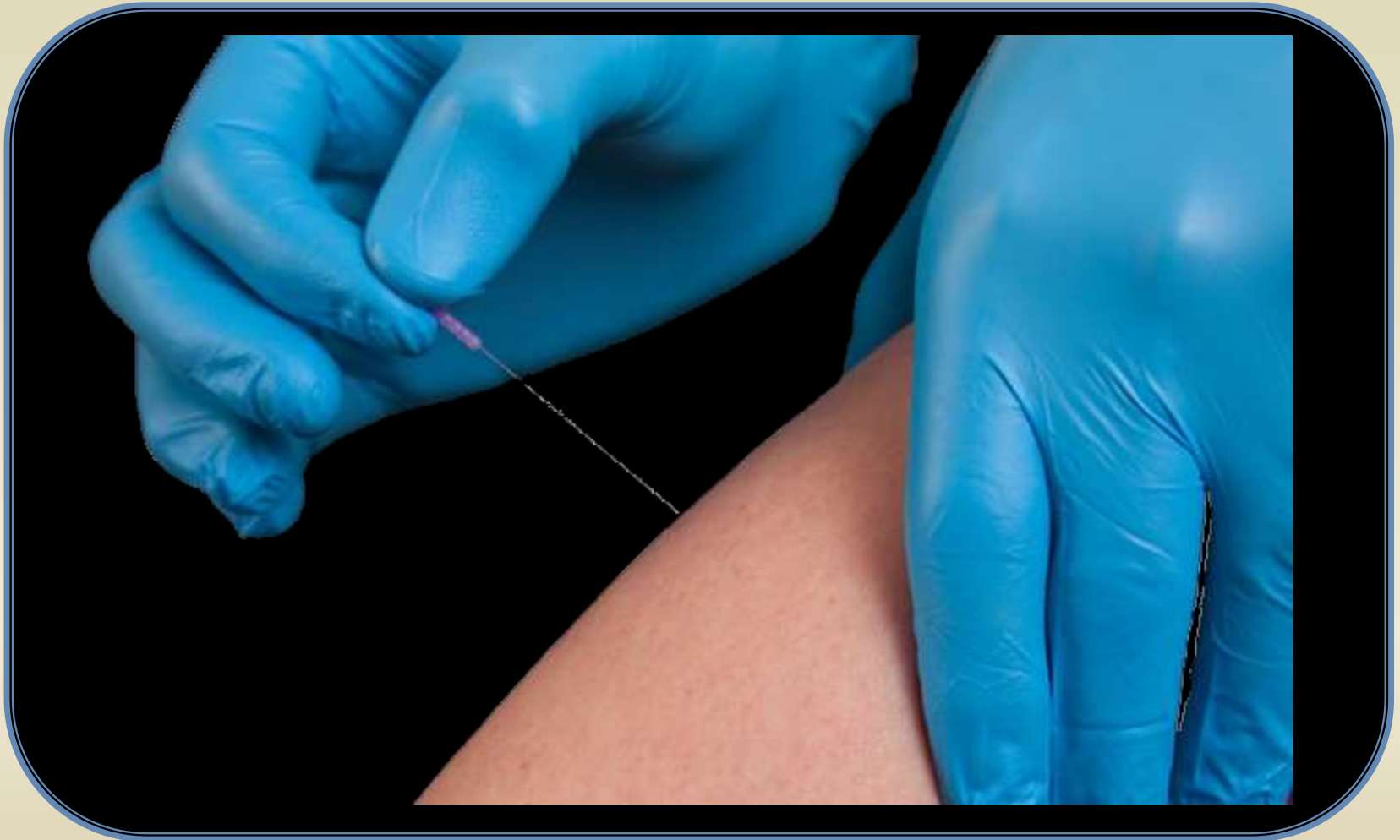Lower Trapezius Examination



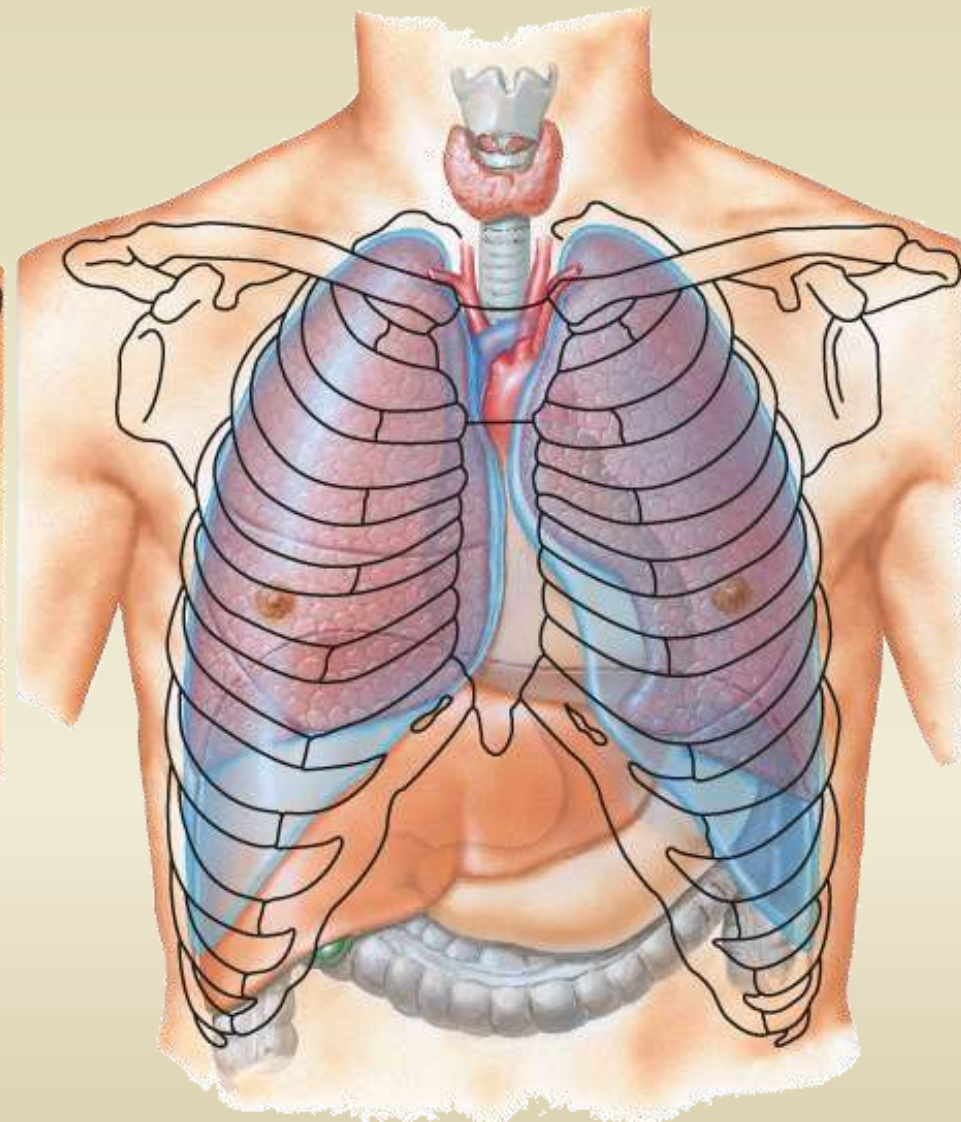
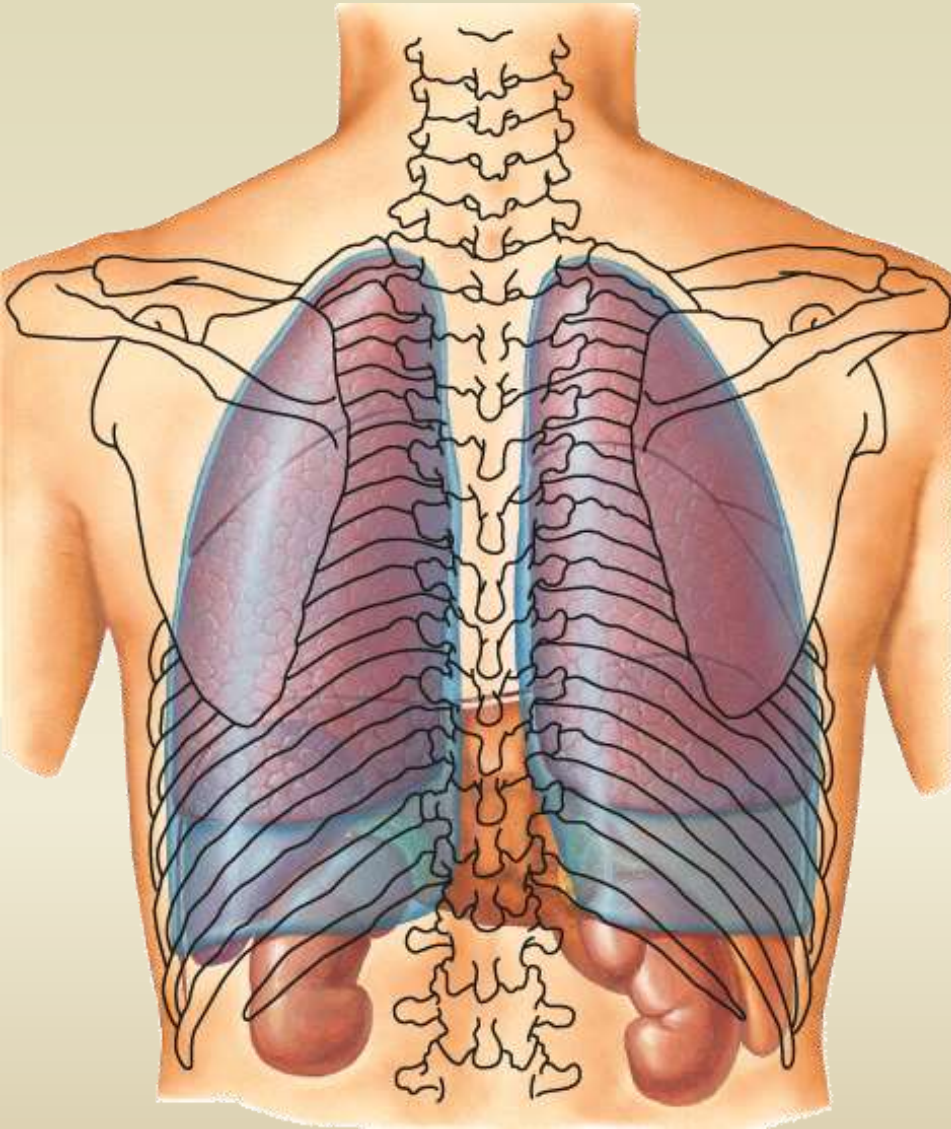
- Kinesio Taping upper extremity workbook ©2005
- Interactive Spine. Primal Pictures ©2003



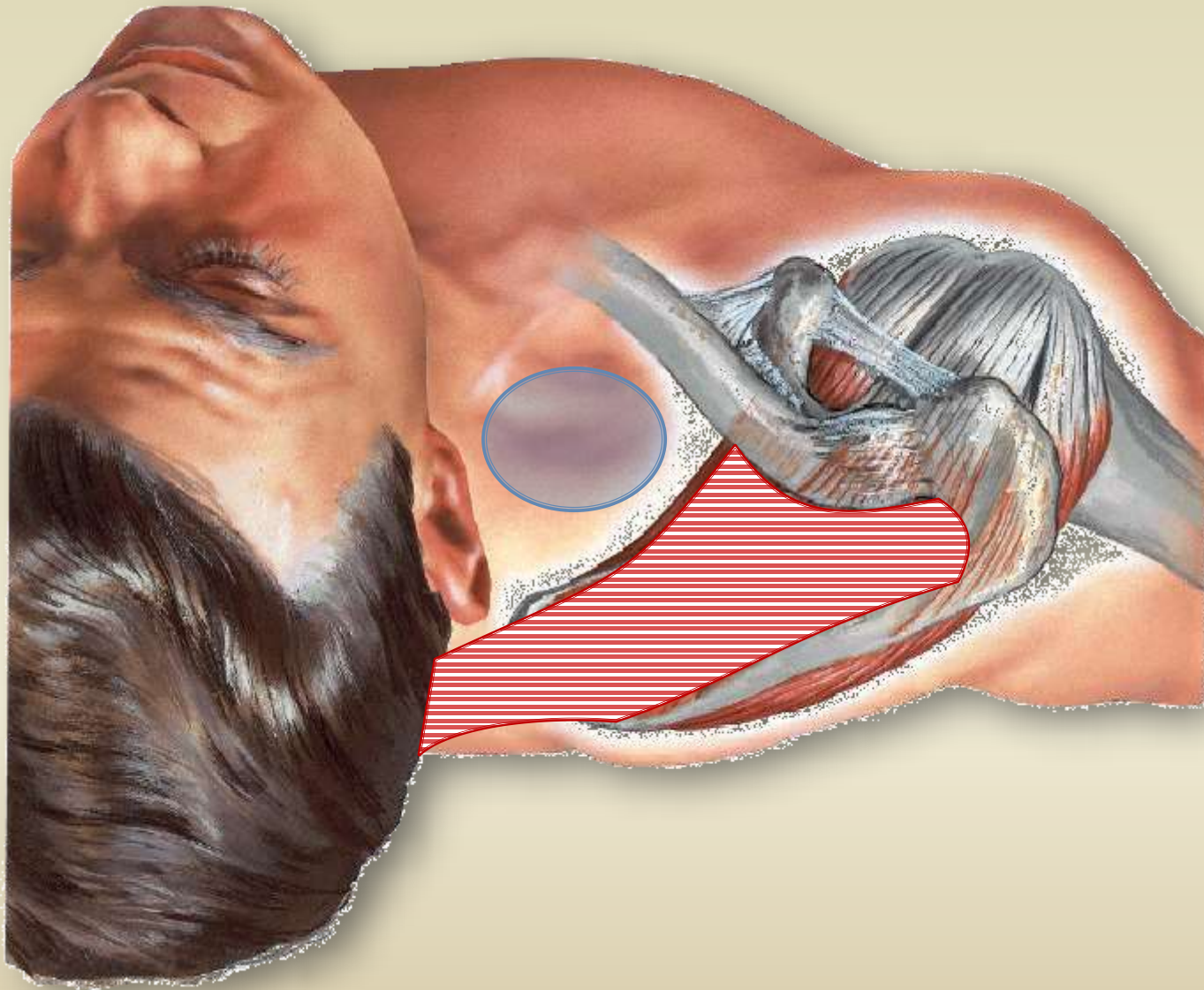
Trapezius Needling



Topography of lungs



View from above



Thank you

Safe

Effective

