



Forearm Pain



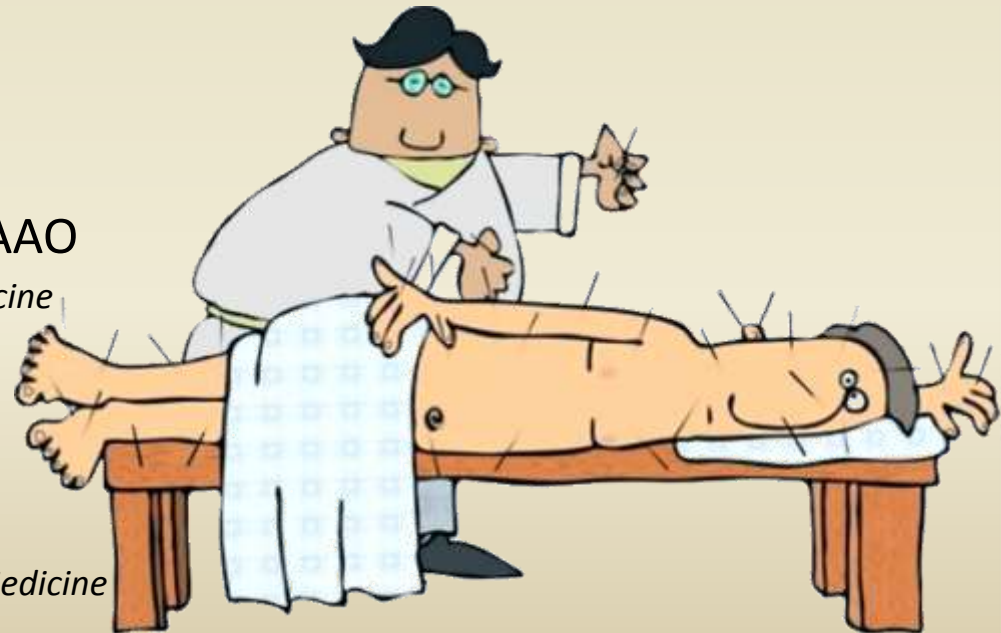Michael Kuchera, DO, FAAO

*Professor of Osteopathic Manipulative Medicine
Marian University*



John Kent, BSc, MD

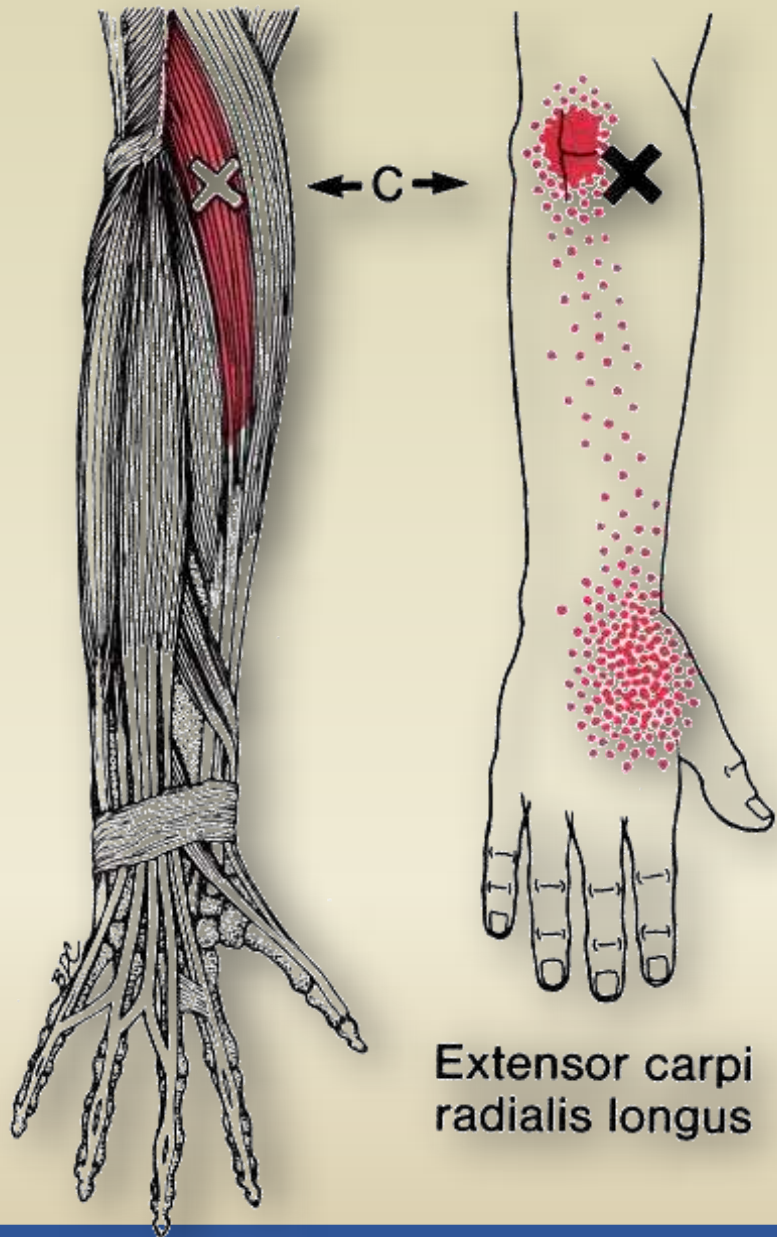
*Rambam School of Pain, Haifa Israel
Founder, Israeli Society of Musculoskeletal Medicine*



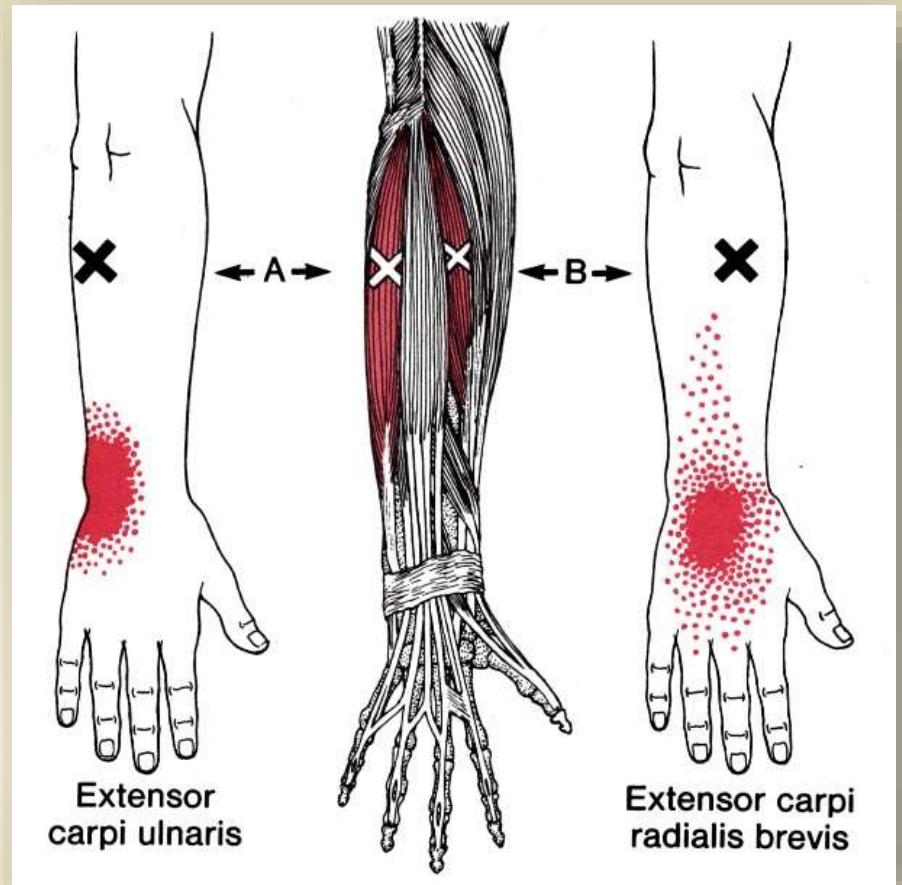
The muscles

- Extensor carpi radialis longus (ECRL)
- Pronator Teres
- Supinator





Extensor carpi radialis longus



Extensor carpi ulnaris

Extensor carpi radialis brevis





Extensor carpi radialis longus

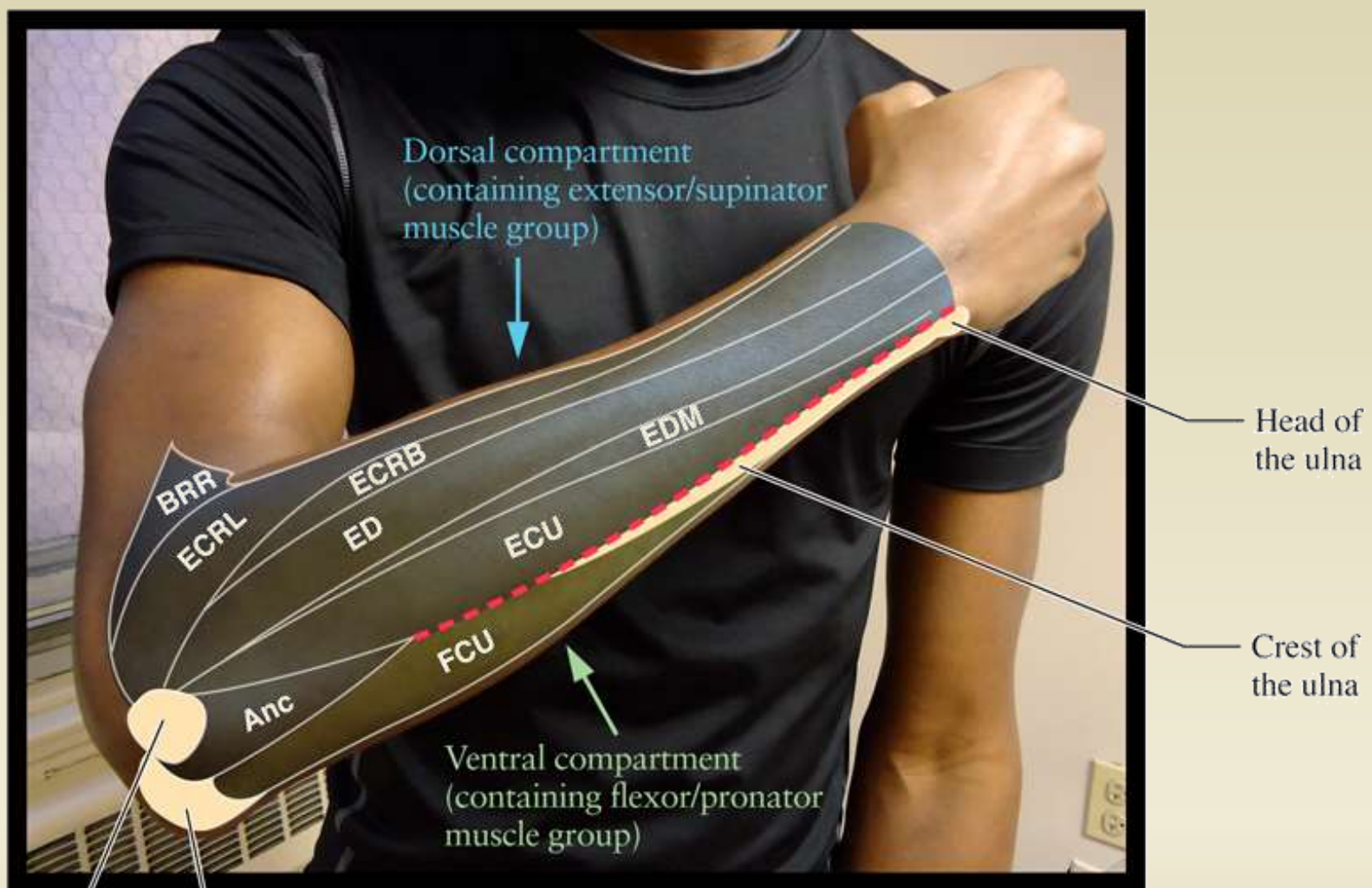
Lateral epicondyle

Extensor digitorum

Brachioradialis

Extensor carpi radialis brevis





Lateral epicondyle of the humerus

Olecranon process of the ulna



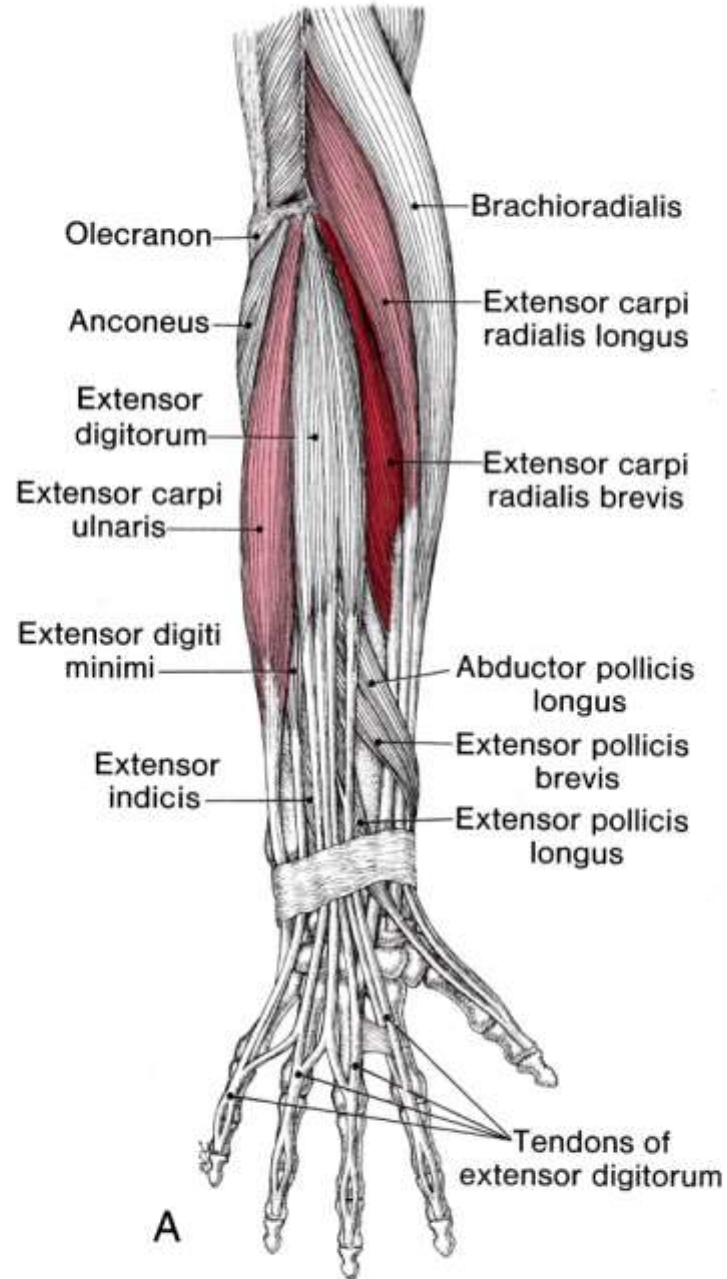
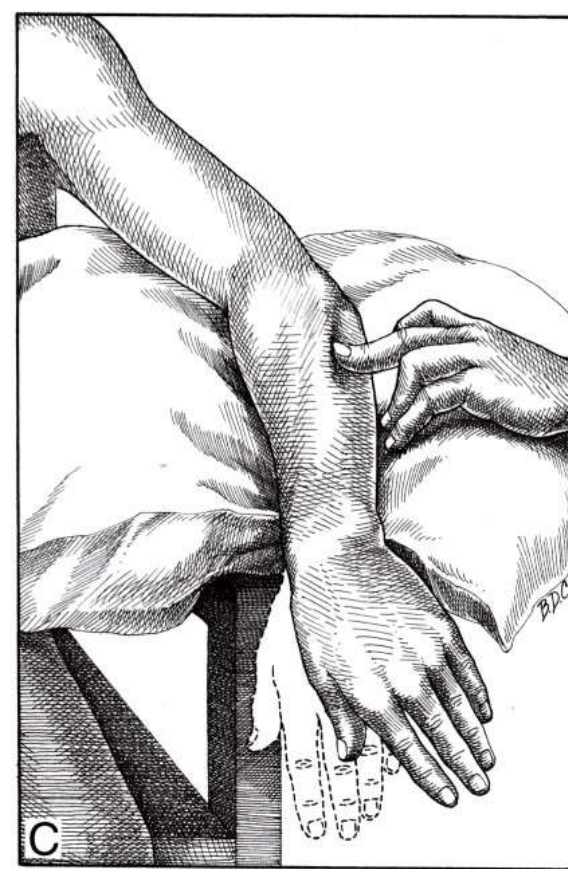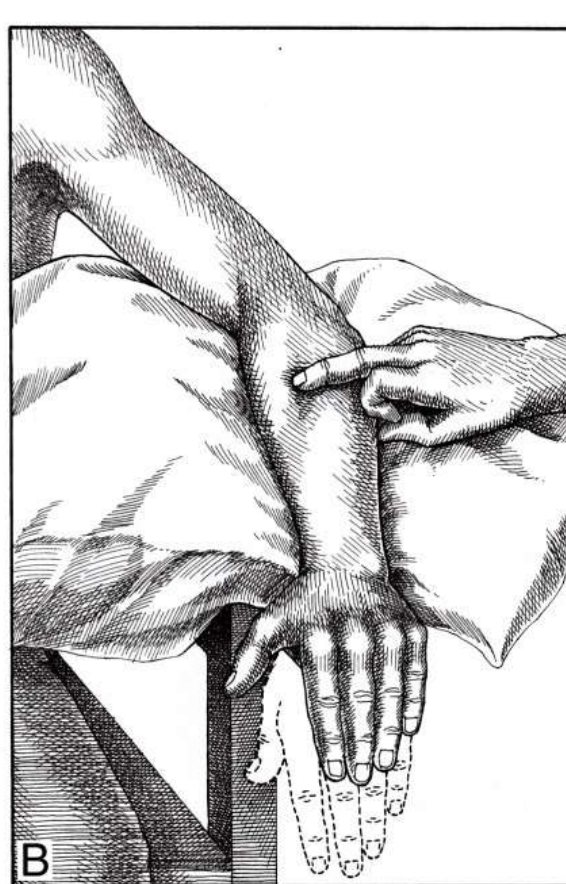

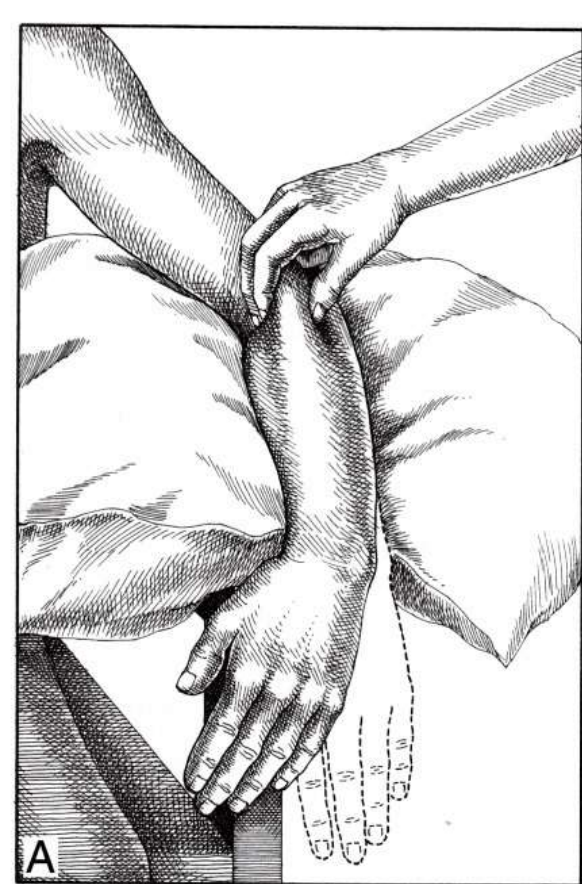
Figure 34.3. The relations of the hand extensor muscles and part of the radial nerve in the right forearm.
A, dorsal view showing the attachments of the extensor carpi radialis longus and brevis, and extensor carpi ulnaris muscles.





Extensor carpi radialis longus
Causes radial deviation of the hand

Extensor carpi radialis brevis
Causes extension at the wrist

Extensor carpi ulnaris
Causes ulnar deviation of the hand

