

VISCERAL GENESIS NONSPECIFIC REFLEX MUSCULAR SYNDROMES

A.M. Mikhailov
Novokuznetsk, Russia
SUMMARY

120 patients with muscular pain syndrome in lumbar region were examined. These patients had confirmed diagnosis of nephroptosis and no kidney abnormal changes at the moment of examination. There were obtained nonoptimality clinical and computer topographic criteria for motor stereotypy static and dynamic constituent in patients with nephroptosis. Three types of regional postural muscle imbalance formation were defined as well as their importance in clinical picture of muscular pain syndrome in lumbar region. Differential visceral manual therapy practice was developed for nephroptosis muscular pain syndrome depending on the type of compensatory overlaid muscles.

•

GROUND ON POSSIBILITIES OF THE MANUAL THERAPY IN TREATMENT OF THE FIRST STAGE IDIOPATHIC AND DISPLASTIC SCOLIOSIS AT CHILDREN

E.A. Shumakov, G.I. Shumacher
Barnaul, Russia
SUMMARY

Authors revealed, that reason of the first stage idiopathic and displastic scoliosis in children is shortening leg and, in consequence of this, pelvis obliquity. The basic reason of the shortening leg is the functional blocking in the pelvis. Treatment include correction functional blocks in the pelvis and on all extent of a backbone, formation of correct motor stereotype, treatment gymnastics.

Correction stayed after liquidation of a pelvis obliquity rib deformation carried out by the means of temporary lengthening of the shortening before treatment leg with the help of orthopedic footwear.

Key words: the first stage idiopathic and displastic scoliosis, children, manual therapy.

•

MANUAL THERAPEUTIC TREATMENT OF CHILD'S STRABISMUS

A. Beliaev, V. Melnikov, M. Yakovleva, I. Stepanov, L. Iarlykova, V. Negoda
Vladivostok, Russia
SUMMARY

Pathobiomechanic changes (PBMC) of Locomotorium, cranial and visceral structures form an important link in child's strabismus development and maintenance. Normalization of motive stereotype decreases a squint angle and improves vision acuteness.

Key words: strabismus, children, manipulation.

•

PATHOLOGY ARTICULATION OF A PELVIS AND OPPORTUNITIES OF MANUAL THERAPY FOR ITS CORRECTION AT THE PREGNANT WOMEN WITH DISEASE SPINE

E.G. Skrjabin
The Tyumen medical academy, Russia
SUMMARY

At 430 pregnant women with disease of a spine conduct manual diagnostics and therapy articulation of a pelvis. Is established in 52,5% of cases are change articulatio sacroiliaca, on the second place on frequency there is as a pathology symphysis pubica – 12,5%, on third – articulatio sacrococcygea – 10,9% of cases.

The efficiency from use of manual therapy for treatment pain in articulation sacroiliaca makes 81,8% of cases, in articulation sacrococcygea – 68,0% of cases. The treatment pain in symphysis pubica has appeared effective in 56,0% of clinical supervision.

Key words: *the pregnant women, pain, spine, articulation of a pelvis.*

●

**CAPILLAROSCOPIA IN SPINAL COLUMN PATHOLOGY AND IN ESTIMATION OF ITS MANUAL THERAPY TREATMENT EFFICIENCY
(clinical and instrumental examination)**

**V.A. Frolov
Moscow, Russia
SUMMARY**

The article tells about the necessity of capillaroscopy further development and implementation in manual therapy. There were detected and defined the features of microcirculation bloodstream state depending on the autonomic nervous system original state and on the spinal column elements position. It allows not only to define the individual level of peripheral circulation disturbance, but also to assure the effective adequate control of recovery process after manual therapy treatment.

Key words: *capillaroscopy, microcirculation, capillaries, venules, arteriolae, manual therapy.*

●

INFLUENCE OF COMPLEX TREATMENT USING MANUAL THERAPY FOR BIOCHEMICAL INDEX OF THE BLOOD PLASMA IN PATIENTS WITH OSTEOHONDROSE OF SPINE IN STAGE OF EXASPERATION

**E.A. Degtev, F.H. Kamilov, I.V. Erofeeva
Ufa, Russia
SUMMARY**

The article contains results of research of connective tissue exchange, intensity of lypoperoxidation and endogenous intoxication of patients with osteohondrose of spine in stage of exasperation. Stated that complex treatment with using of manual therapy promotes a normalization of metabolism collagen and proteoglycans, level molecule medium mass, index of endogenous intoxication and peroxidize oxygenation lipids. It is substantiated an importance of including in complex of treatment pharmaceuticals which have antioxidant action and improve functions of detoxication organs.

●

THE QUANTITATIVE AND SPATIAL–TOPOGRAPHICAL CHARACTERISTICS IMPELLENT SYNENERGYS OF THE TOP EXTREMITY OF THE MAN IN NORM

**K.B. Petrov, D.M. Ivanchin
Novokuznetsk, Russia
SUMMARY**

In a basis of nonspecific reflex – muscular syndromes pathological stabilization born impellent synergy lays. Impellent synergys hands of the person differ phylogenetic heterogeneity. With the help electromyography their spatial – topographical characteristic in norm is investigated. The received data can be useful at rehabilitation painful and spastic paralysis syndromes of the top finiteness.

Key words: *electromyography, synergy, philogenesis, a muscular tone, rehabilitation.*



IS MANUAL THERAPY A HAZARD TO HEALTH?

Dr. Michael Hutson
Musculoskeletal physician, UK
Vice - president FIMM

Musculoskeletal complaints may be made worse, or even caused primarily, by Manual Medicine interventions. At the very least, reinforcement of morbidity is always a potential risk of manual treatment. Dependency, chronicity of symptoms, and disability are often the consequence of inappropriate clinical involvement, in addition to socio/cultural factors.

The biopsychosocial model has been acclaimed as a Kuhnian paradigm shift, but much manual treatment continues to address the biomedical model. Increased focus (by the medical establishment) on the environment that makes people sick rather than sickness as such is recommended.

This presentation outlines the hazards for the patient associated with Manual Medicine practice, and proposes greater emphasis on medical education in the behavioural and social sciences.

•

FREQUENCY OF ACCIDENTS AFTER SPINAL MANIPULATIONS

M.J. Teyssandier, MD
General Secretary of ULEMMA
56 Ave Joseph Giordan – F – 06200, NICE, France

The frequency of serious accidents after spinal manipulations (SM) is unknown. Only estimations are possible. We are aware of less than 10% of the true accidents after SM. For France we value their minimal frequency at 2 per million of SM, and 2 vertebro-basilar accidents (VBA) per million of cervical spine manipulations (CSM). In the world, these two values are very conflicting (from 0.2 to 50 VBA per million of CSM). It is difficult to compare our statistics to these published in the US editorials because the word "manipulation" has not the same definition in each country. In all the cases, it's not very much in comparison with the frequency of major iatrogenic effects of NSAID's treatments.

Regarding 250 cases of accidents published, in 80% of them it's a VBA after CSM. For 75% of the cases of VBA, they appear after a CSM with a thrust resulting from a rotatory impulse. In order to limit the risks of VBA, the thrust must result from a translation or side bending impulse.

Teyssandier MJ. Fréquence des accidents après manipulations vertébrales.

La Riabilitazione (Ital.) 2000 ; 33 (3) : 121-127.

Teyssandier MJ. Tchatota oslajneniy posle manipouliastsiy na cheinom otdele

Pozvonotsnikha vo frantsiy i soedinennikh chtakakh ameriki.

Manoualnaia Terapiya (Russie) 2002 ; 1 (5) : 3-8.

Vautravers P., Maigne JY. Fréquence des accidents vasculaires après manipulations vertébrales cervicales.

Rev. Rhum. (F.) 2000; 67: 349-354.

•

EFFECTIVENESS OF MANUAL THERAPY ON THE CERVICAL SPINE (EVALUATION OF NECK MOBILITY, NECK POSTURE AND NECK MUSCLE STRENGTH)

Dr. G. Ormos, MD
National Institute for Rheumatology and Physiotherapy, Budapest, Hungary

40 patients (20 male and 20 female, mean age 38,6 years, duration of their symptoms between 1-6 months) have been treated by manual therapy because of pain and movement restriction of the cervical spine. Their diagnosis was degenerative spine disease without neurological symptoms. Their neck mobility, neck posture and isometric neck muscle strength have been measured.

●

MANUAL THERAPY IN COMPREHENSIVE TREATMENT OF PATIENTS WITH COMPRESSION SYNDROMES OF LUMBAR OSTEOCHONDROSIS DEPENDING ON THE LOCATION OF INTERVERTEBRAL DISC HERNIAS IN SPACE

Topic theme: Treatment of spondilogenous syndromes.

Hypothesis. The treatment of patients with the compression syndromes caused by hernias of intervertebral discs in the lumbar spine by the manual therapy method should be differentiated and dependent on the location in space of the hernial protrusion.

Materials and methods. 14926 patients in average age of 36 suffered from compression syndromes in lower back due to intervertebral disc herniation were treated. The location of intervertebral disc herniation was determined: 15,1% was median, 83,7%/paramedian, and 1,2%/ foramenal.

Manipulations were conducted at the acute period after giving analgesia. The courses of treatment consisted of 8/ 10 everyday sessions each were repeated during 2/5 years every 2/3 month.

Results. It was found out that the main healing manipulations and mobilizations in clinical manifestations of median disc herniation were frontal flexions with a distraction of lumbar spine. A prohibited direction of movement is bending backwards.

The main healing manipulations in clinical manifestations of lateral and foramenal disc herniation were manipulations and mobilizations of dorsal bending in the affected segment with a simultaneous flexion to the "healthy" side and distraction. Prohibited movement is bending forward.

The main criterion of the efficiency of treatment, in our opinion, is the elimination of the pain syndrome. The range of active movements in the whole lumbar spine was unlimited, with a simultaneous restriction of passive movements in the effected segment.

Conclusions. The research conducted by our Center confirms that the comprehensive therapy of the patients with severe compression syndromes of the lumbar spine is quite successful if its realization and duration (1,5 month – 5 years) are correct and strictly selective.

●

THE ROLE OF MANUAL THERAPY AMONG OF REFLEX METHODS IN DISCOGENIC RADICULOPATHIES' TREATMENT

Objectives. To substantiate the differential approach to use of various reflex methods in complex restoration treatment of discogenic lumbar/sacral radiculopathies caused by intervertebral disc herniations.

Methods. Seventy-four patients with clinical appearance of lumbar/sacral radiculopathies caused by intervertebral disc herniations, which was proved by magnetic resonance imaging, were divided into three groups depends on carried out variant of treatment. In two main groups against a background of standard medicine and orthopaedic treatment reflex therapy was carried out: 25 patients (I group) were treated with acupuncture (AP), 25 (II group)– with manual therapy (MT). In third group were included 24 patients treated with standard medicine and orthopaedic methods.

The estimation of pain intensity according to the visual analog scale (VAS), emotional/affective disorders according to Hamilton scale and analysis of moving stereotype (MS) evolution stages were carried out before and after the treatment to compare its results in various groups (V.P. Veselovsky, 1991). As a criterion of evaluation was chosen the period of change one MS stage by another, independently of stage registered at the beginning of treatment. Dynamics of neuro/ vascular disorders of lower extremities were estimated by analysis of reovasographic indices.

Results. Use of MT directed on intervertebral joints' blockades removing and optimization of correlations in vertebral moving segments cooperated with damaged one allows to accelerate the optimization of pathologically changed MS ($p < 0,05$).

The evaluation of pain intensity dynamics gives evidence about earlier anaesthetic effect of AP ($p < 0,05$), its high effectiveness in strong neuro/vascular disorders ($p < 0,05$) and depressive disturbances ($p < 0,05$).

Conclusions. The differences in mane effects of MT and AP in discogenic lumbar/sacral radiculopathies on the one hand open the possibility of their differential use and on the other hand says about expediency of combined use of these methods.

COMPARATIVE EFFECTIVENESS OF METHODS OF MANUAL MEDICINE IN TREATMENT OF MYOFASCIAL PAIN SYNDROME IN PATIENTS WITH NATAL TRAUMA OF CERVICAL SPINE

Ivanichev G.A., Kuznetsova EA.

Department of neurology and reflexotherapy, Kazan state medical academy, Kazan, Russia

The aim of the study was to give clinical and instrumental characteristics of myofascial pain syndrome (MPS) in patients with natal trauma of cervical spine and to evaluate different methods of treatment of MPS associated with natal cervical trauma.

MATERIAL AND METHODS

Fifty patients with clinical manifestations of MPS of neck and shoulder girdle have been examined and treated. 34 of them were the adolescents with MPS in combination with natal cervical trauma (the average age was 13,7±0,6) and 16 – the group of patients without natal trauma (the average age was 15,6±0,5). All patients were neurologically examined in order to exclude organic pathology of the nervous system. Patients with severe chronic diseases of inner organs also were not included into study. The patients of both groups were divided into few categories: I – the patients who were treated by physiotherapy and medical therapy, including improvement of blood circulation in cervical region and analgesics if necessary; II – the patients who were treated by medical therapy in combination with the methods of manual medicine, including application of massage to the taut band, TrP pressure release and stretch/release techniques; III – the same in combination with dry needling of TrPs.

Such methods as pressure algometry and myotonometry were used before and after treatment. These methods allow to estimate clinical manifestations of MPS, in particular TrP painfulness and muscle tone, in dynamics of pathological process and, therefore, to evaluate effectiveness of TrP therapy. Sensivity to pain in patients with TrPs has been measured as the pain threshold to applied pressure. Three parameters have been reported in each patient: pressure pain threshold (the onset of local pain), referred pain threshold (the onset of referred pain) and pain tolerance (intolerable pressure) [Travell J.G., Simons D.G., Simons L.S., 1999]. These parameters were measured in kilograms. Myotonometry allows to measure degree of muscle deformity in mm in response to applied pressure from 0 to 5 kg.

RESULTS

Clinical examination and pressure algometry and myotonometry findings showed that the best therapeutic effect was presented in the third group of patients. In this group of patients, who received complex therapy in combination with dry needling of TrPs, clinical improvement of symptoms was observed: pain relief, decrease of muscle painfulness and increase of pain threshold and pain tolerance to applied pressure. The therapy of patients of the second group was less effective, but the symptoms improved in comparison to initial data. In both groups of patients myotonometry revealed decrease of muscle tone which was measured after few procedures of postisometric relaxation of involved muscles. Physiotherapy and medical therapy without using methods of manual medicine turned out to be ineffective. The clinical effect was insignificant and not stable. Pressure algometry and myotonometry showed no difference in comparison to initial parameters in that group of patients.

CONCLUSION

According to the clinical and experimental data, complex therapy, including medical treatment, methods of manual medicine and myopuncture, is the most adequate and effective in treatment of patients with myofascial pain syndrome associated with natal trauma of cervical spine.

•

MORPHOMETRIC CHANGES OF THE CARPAL TUNNEL AFTER MANUAL THERAPY TECHNIQUES. A COMPUTED TOMOGRAPHY STUDY IN ASYMPTOMATIC VOLUNTEERS

P.M. Dugailly^{1,2}, V. Feipel¹, V. Schepers^{1,2}, M. Rooze¹

¹ Laboratory for Functional Anatomy and Department of Anatomy and Embryology, Université Libre de Bruxelles;

² Department of Physical Therapy and Rehabilitation, Erasme Hospital, Brussels

INTRODUCTION

Carpal tunnel syndrome is a very common peripheral nerve compression syndrome. Dimension modifications of the carpal tunnel with subsequent over/pressure of the neural structures are described in the physiopathology of this entity. Therapeutic approaches of this syndrome are diversified. According to the literature each treatment such as surgical, medical and physical approach might provide relief (4). In the field of manual therapy, mobilisation of the carpal bones it is suggested to stretch soft tissue structures such as flexor retinaculum (FR) to modify carpal tunnel dimension (1,2,3). Therefore, these mobilising techniques are expected to improve either pressure upon the nerve or its blood flow. This

study aims at investigating morphometric changes of carpal tunnel dimension after carpal mobilization in asymptomatic subjects.

METHODS

18 volunteers (14 females and 4 males, age: 20/52 years) without any upper limb complaint participated in this study. Each subject was evaluated before and after the mobilization session. Each treatment, comprising 4 manoeuvres (3 stretching techniques and one FR relaxation technique), was performed on the right wrists by the same operator. Each manoeuvre was applied during one minute. Manoeuvres were repeated to obtain a total treatment duration of ten minutes.

Before and after intervention, carpal tunnel dimension were analysed using computed tomography. Acquisition of carpal imaging was conducted in a palm against palm position with the wrists in neutral position. Using one or two slides at the level of the hook of the hamate and trapezium tubercle, morphometric parameters such as FR length (L), anteroposterior distance (D) and carpal tunnel perimeter (P) and cross sectional area (A) were digitized and computed using image Tool 1.27 (UTHSCA, Tx, USA) (figure 1). To assure reproducibility of assessment each digitizing was performed three times for each variable. The current work was approved by the ethical comity of the Medical Faculty. Statistical analysis was performed using MANOVA for repeated measures and Pearson coefficients of correlation. Control of distribution and homogeneity of variances was conducted using Kolmogorov/Smirnov and Levene tests.

RESULTS

In our sample, normal distribution was found for all variables and homogeneity of variance was observed. According to MANOVA, no significant influence of digitizing repetition and dominance on data was found for all parameters. In general, good correlation ($0.86 < r < 1.00$) between repeated measurements was demonstrated for each parameter independent of the sessions (pre – post).

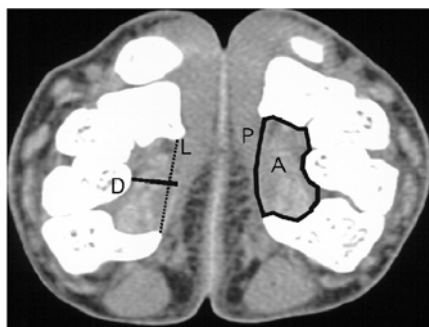
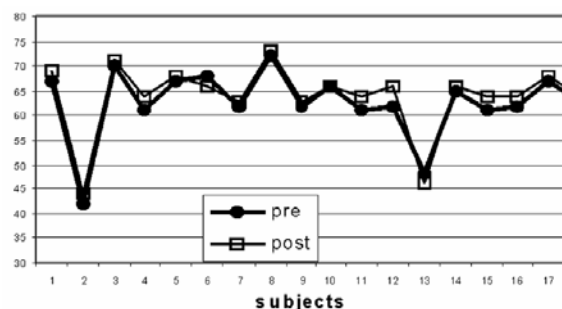


Fig.1: Cross sectional area of the carpal tunnel



Concerning manual treatment, no significant difference was found between pre- and post/session on carpal tunnel dimension. There was no difference between dimensions in the control and treated hands, either before or after treatment. Moreover no interaction between independent variables has been demonstrated. Linear correlation was also observed between pre- and post/treatment data with coefficients ranging from 0.73 to 0.98. Figure 2 illustrates the evolution of FR length before and after treatment for the entire population.

DISCUSSION

The current protocol has demonstrated good digitizing reproducibility for all analysed parameters. Our data are similar to those related in the literature regarding cross sectional area and FR length (1, 2). The influence of manual techniques on the dimension of the carpal tunnel is controversial in the literature and results are variable due to the multiplicity of manual approaches (1,2,3,4). The results of this study showed that a single short application of manual techniques has no significant effect of the carpal tunnel dimension parameters of asymptomatic subjects.

REFERENCES

1. Winn FJ et al. (1990), Muscle and nerve; 13:254/258
2. Sucher BM (1993), JOAO ; 1273/1278
3. Ramey KA et al. (1999), AAOJ ; 25/32
4. Tal/Akabi A et al. (2000), Manual Therapy ; 214/222

CLINICAL AND XRAY PARALLELS POST HERPES PAIN SYNDROME

V. V. Malahovsky, A. M. Orel, MMA im. I. M. Sechenova

We did clinical and X-ray investigations of 9 patients with post herpes pain syndrome. The integral study of the spine roentgenograms ISSR – method used. It was show stable vertebrae displacement on post

herpes lesion level in all cases. ISSR – method is useful for recognition and registration vertebrae displacement patients with post herpes pain syndrome.

•

NEW THOUGHT PARADIGM RADIOLOGICAL DIAGNOSTICS IN MANUAL THERAPY

A. M. Orel
MMA im. I. M. Sechenova

The system for recognition, registration and transmission of every part of the useful information is proposed. The information about each patient spine peculiarities is present to a therapist in the most convenient form. The system includes: the spine radiography standards; graphical form (study report blank); tools and techniques for recognition and registration of the radiographic finding; designations; diagnostic algorithm. The system was named «The integral study of the spine roentgenograms» (ISSR). Above two thousand patients treatment experience using the integral study of the spine roentgenograms (ISSR) demonstrates its high efficiency for rehabilitation programs development and executing under the guidance of manual therapists. The ISSR technique shows the new possibilities for actual science and practice problems solving in manual therapy, rehabilitology, orthopedics, and biomechanics.

•

ELECTROPHYSIOLOGIC MECHANISMS OF F/WAVE AND H/REFLEX FORMATIONS IN PATIENTS WITH DYSTROPHIC INJURY OF INTERVERTEBRAL DISKS

Valeriy Belyakov
Region manual therapy center, Obninsk, Russia
Tel/Fax: +7 (08439) 44560; belyakov2@obninsk.com

Electroneuromyographic methods gain in more and more importance for diagnosing affection of the peripheral nervous system. The application of F/wave and H/reflex for investigating the most proximal sections of cerebrospinal nerves – anterior and posterior roots of the spinal cord – takes on practical significance and is of special interest.

40 patients with reflex and compression syndromes at the neck and lumbar levels accompanied by laterality of pain syndrome have been examined. Investigations of M/ amplitude and a maximum conduction velocity (MCV) along motor fibers of the median and tibial nerves, F/wave, H/reflex on the injured and intact sides, were done for each patient. No changes of the M/ amplitude and the MCV along the motor fibers have been revealed in the group of patients with reflex syndromes. The increase of F/wave and H/reflex amplitudes has been recorded on the injured side. The decrease of the M/response amplitude when the MCV along the motor fibers remained without changes, the decrease of F/wave and H/reflex amplitudes on the injured side have been recorded in the group of patients with compression syndromes.

Thus, the electrophysiologic mechanism of formation of the reflex pain syndromes is an imbalance between the hyperactive extero- and proprioceptive reception at the posterior horn level. It results in considerable reduction of activity of the “portal control” mechanisms and establishes the neurophysiologic base for forming a pathologic generator system in the posterior horn area, which is proved by the increase of F/wave and H/reflex amplitudes on the injured side. The decrease of F/wave and H/reflex amplitudes on the injured side is recorded under the conditions of the compression syndrome formation due to direct injury of the cerebrospinal roots.

•

ULTRASOUND IMAGING POSSIBILITIES IN DIAGNOSTIC OF INTERVERTEBRAL DISK DEGENERATION WITH NECK PAIN SYNDROME

I. Sharapov, V. Belyakov
Region manual therapy center, Obninsk, Russia

Ultrasound imaging methods have been widely spread in latest years for intervertebral disk degeneration diagnostic, because of high visual possibilities of modern ultrasound scanners.

The results of ultrasound and MRI diagnostic for 24 patients with neck pain syndromes were compared. The research was held on scanner «Aloka/1700» by microconvex detecting element with 5MHz

frequency. The scanning was conducted through paratracheal access in sagittal and axial planes. Intervertebral disks C3/C7 were accessed for the research.

The total amount of researched intervertebral disks is 96. The ultrasound sensitivity on disk degeneration comes to 92%, specificity – 90%. The sensitivity on disk herniation comes to 88,6%, specificity – 98,3%. Sensitivity for sizes changes of spinal canal – 90,9%, specificity – 100%. The ultrasound criteria for disk degeneration stages were defined also. Thus, ultrasound imaging at cervical spine let diagnosing dystrophic changes at different stages, that allowed assigning a substantiated treatment in short time.

In condition of out/patients“ clinic reception ultrasound imaging has a number of advantages: they are a comparative simplicity of the method equally with high informativity, availability, safety, cheapness, the ability of recurrence usage including for therapy efficiency control.



SOME ASPECTS OF SPINE «FLAIL» INJURIES FROM THE POINT OF MANUAL THERAPY

Yu.B.Moiseev, A.T.Neborsky
Moscow, Russia
SUMMARY

Experiments with participation of volunteers showed, that impact accelerations, which were registered during transport incidents (7...25 G), caused disorders of spine and signs of moderate «flail» injuries. The volunteers had pain, some restriction of spine mobility and rotation of vertebra of damaged spine segments. Manual therapy completely and quickly corrected these disorders.

DORSALGIA TREATMENT BY SEGMENTAL POSITIONING METHOD

Yu.V. Chikurov
Tavrishesky National University named after V.I. Vernadsky, city of Simferopol, Ukraine
SUMMARY

A new method for correction of abnormal mobility of vertebral motor segment (VMS) in case of dorsalgias – segmental positioning has been proposed and put into practice. This method consideration is possible in the frames of the modern paradigm of manual medicine. Diagnostic methods of “abnormal mobility pattern” of VMS and segmental positioning therapeutic techniques have been developed. These techniques make it possible to correct the abnormal mobility of VMS quickly, painlessly and safely for a patient. Practical application has proved the method high efficiency.

Key words: *manual medicine, dorsalgia, segmental positioning.*

NONSPECIFIC REFLEX–MUSCULAR SYNDROME OF INHIBITION BENDING LOCOMOTAR HAND'S SINERGY

K.B. Petrov, D.M. Ivanchin
Novokuznetsk, Russia
SUMMARY

At patients with reflex – muscular syndromes of a cervical osteochondrosis on the interested top finiteness oppression typical for healthy people «bending – adducting – pronator» a tone of rest is observed, that especially is expressed in top departments of region. During treatment amplitude EMG grows, however the tendency to its common decrease is kept. On this background some revival extensor tonic reactions is observed.

Key words: *electromyography, synenergy, a muscular tone, a cervical osteochondrosis, trigger point, rehabilitation.*

COMPLEX TREATMENT OF NEUROLOGIC MANIFESTATIONS OF LUMBAR OSTEOCHONDROSIS USING MANUAL THERAPY AND APITHERAPY METHODS

R.S. Iskuzhin, A.F. Gallyamova, Yu.O. Novikov
City of Ufa, Russia

SUMMARY

There were examined 65 patients with neurologic syndromes of lumbar osteochondrosis; 32 of them were treated with the course of manual therapy, and the rest 33 with the course of complex therapy including apitherapy (bee stings). The groups did not have statistically authentic distinctions in the characteristics of the illnesses. The efficiency of the applied treatment was estimated on the base of dynamics of clinical and neuroorthopedic investigations. The use of the apitherapy in the complex with manual therapy let us to get more expressed clinical effect on the patients with neurologic developments of lumbar osteochondrosis.

Key words: *neurologic syndromes of lumbar osteochondrosis, manual therapy, apitherapy, treatment.*

•

SYSTEM CONCEPT OF HUMAN SPINE DEVELOPMENT AND CHANGE**A.M.Ourel**

Department of therapy non-medicinal methods and clinical physiology with psychotherapy and clinical psychiatry course, Moscow Medical Academy named after I.M. Sechenov, Russia

SUMMARY

Child's spine development is considered as a natural physiologic process in general medical practice. Contrary to it, dystrophic changes of the spine are considered as a disease. Spine system study from embryonic period till the extreme old age has revealed resemblance of X-ray picture of children's special features of the spine development and dystrophic changes of an adult. This fact made it possible to formulate a hypothesis in accordance with which dystrophic changes were caused by influence of the same mechanisms and factors of the external and internal environment, which conditioned the child's spine development, but these mechanisms and factors influenced under the conditions of the completed osteogenesis.

Key words: *spine as a system, spine development, spine dystrophic changes, mechanism of development of dystrophic changes of vertebrae.*

•

TO THE PROBLEM OF REHABILITATION OF CHILDREN AND TEENAGERS HAVING ATTITUDE ABNORMALITIES AND SCOLIOTIC DEFORMATIONS BY MANUAL THERAPY METHODS**T.A. Shitikov**

Traditional Medicine Institute, city of Dnepropetrovsk, Ukraine

SUMMARY

By clinical and biomechanical results of treatment children and teenagers with scoliosis, analyzes expediency of manual therapy using by patients with infringements of bearing and scoliosis deformations to biomechanical criteria. The distribution of the patients on subgroups is investigated depending on biomechanical, clinical attributes.

Keywords: *scoliosis, biomechanical change, manual therapy.*

•

CLINICAL BIOMECHANICS AND PATHOBIOMECHANICS OF SHOULDER-GIRDLE**A.V. Stefanidi**

Irkutsk, Russia

SUMMARY

The algorithms of visual and manual diagnostics of optimal and nonoptimal static and dynamic of shoulder girdle are given in the article. Visual criteria of pathobiomechanics at shortening and weakening of main muscles of shoulder girdle are shown.

**CLINICO-ULTRASONOGRAPHIC COMPARISONS IN PATIENTS WITH PAIN SYNDROMES OF
CERVICAL OSTEOCHONDROSIS**

A.B. Sitel*, V.S. Parshin, I.N. Sharapov, V.V. Belyakov, N.P. Yeliseev**

***The Manual Therapy Center of the Ministry of Health of the Russian Federation, Moscow, Russia;**

****Medical Radiological Research Centre of the Russian Academy of Medical Sciences (MRRRC
RAMS), Obninsk, Russia; Kaluga Regional Manual Therapy Center, Obninsk, Russia**

SUMMARY

The article describes the results of complex clinical and ultrasonography studying of 106 patients with cervical pain syndromes. The meaning of structural changes in intervertebral disks is shown at developing mechanisms of cervical pain syndromes. The values of cervical spine ultrasonography diagnostic have been found in comparison with MRI.

•

**COLOUR DUPLEX SCANNING OF BRACHYCEPHALIC ARTERIES AS A CONTROL METHOD OF
THE THERAPY DYNAMICS OF PATIENTS WITH CERVICOCRANIALGIA UNDER THE CONDITIONS
OF OUTPATIENT VERTEBRO-NEUROLOGIC DEPARTMENT**

Clinico-instrumental study

I.G. Lugova, V.A. Frolov, O.E. Yemelyanova, D.V. Bykov

**Outpatient department №1 of the Medical Center of the Administration of the President of the
Russian Federation, Moscow**

SUMMARY

The lead research of 18 patients with cervicocranialgia treated in vertebroneurological unit shown high significant color duplex sonography of the carotid and vertebral arteries for specification of the diagnosis, definition of indications and choice of management of these patients. The maximal changes were observed in dynamics circulatory on intervertebral segment of vertebral arteries at much smaller fluctuations dynamics circulatory on other sector of brachycephalic arteries during management. It was reflected in reduction of a gradient of a difference of blood circulation between V1 and V2 segments of vertebral arteries. These changes were marked already after the first visit of a doctor of manual therapy. That can assist in difficult diagnostic cases at selection of patients for management by methods of manual therapy.

Key words: color duplex sonography, vertebralbasilar pool, neck manipulation, manual therapy.

•

**MANUAL THERAPY IN TREATMENT OF CONSEQUENCES OF THE BIRTH TRAUMA IN A
CERVICAL DEPARTMENT OF A SPINAL CORD AT CHILDREN OF THE FIRST HALF-YEAR OF A
LIFE**

E.A. Shumakov, G.I. Schumacher, Z.F. Akinina, M.P. Kuznetsova

The Altay state medical university, the Altay regional clinical children's hospital, Barnaul, Russia

SUMMARY

Article is devoted to manual therapy of such consequences of the birth trauma in a cervical department of a spinal cord at children of the first half-year of a life, as a neurologic curvature of a neck, an infantile scoliosis, disorders of a tone of the top and low extremities, a delay of impellent development. Authors developed own methods of the manual therapy in a combination to treatment gymnastics at that pathology and investigated results of application of these methods in clinical practice.

Key words: manual therapy, birth trauma in a cervical department of a spinal cord at children.

•

REHABILITATION OF CHILDREN WITH FUNCTIONAL DISORDERS OF THE LOCOMOTOR SYSTEM CAUSED BY THE DELAY OF CONVERSION OF PRIMITIVE LOCOMOTOR REFLEXES (PLR)

T.A. Shitikov

Folk Medicine Institute, city of Dnepropetrovsk, Ukraine

SUMMARY

Clause is devoted to brief supervision over efficiency of rehabilitation of children with functional infringements of locomotor system caused by a delay of converting primitive motor reflexes. The author used cardijgrafic analysis for diagnostics and dynamic supervision over children at treatment by various methods of manipulative therapy.

•

CRANIOMETRIC CHARACTERISTICS OF CONDYLES OF THE HUMAN OCCIPITAL BONE

A.I. Nebozhin, G.R. Drozhzhina

Russian Medical Academy of Post - graduate Education, Moscow, Russia

SUMMARY

Research 194 nativ crania has revealed asymmetry of development condilus an occipital bone in 99,9 % supervision. Asymmetry of length, height, width condilus and their spatial orientation had statistically significant distinctions of parameters between two parties. At 20,1 % of crania morphometric condilus parameters populations had deviations overstepping the bounds of norm. In this group of crania angular orientation condilus to sagittal axes had statistically significant differences from parameters of the general sample.

•

SOMATIC INTEGRATION METHOD

Yu.V. Chikurov

Crimean State Medical University, Ukraine

SUMMARY

New medical rehabilitational way of the SOMATIC INTEGRATION is offered, permitting to normalize balance of muscles and vela, and also to harmonize the somatic and emotional status of the patient.

Keywords: somatic integration, a locomotors pattern, the somatic status.

•

MANUAL THERAPY APPLICATION FOR TREATING CHRONIC BRONCHITIS: THEORETICAL SUBSTANTIATION OF THE APPLICATION, AN ALGORITHM OF THE MANUAL THERAPEUTIC ACTION, THERAPY EFFICIENCY EVALUATION

I.V. Meshcheryakov

“Sanatorium (resort) “Krainka” LLC, Tula region, Russia

SUMMARY

On staffs of overseeing the groups of 65 persons who are suffering affliction chronic notob structive bronchitis, and from 11 persons who are suffering affliction chronic obstructive bronchitis, detect changes in a referencepro pulsion system, reference for these disease, the authoring explanation of influencing of these changes on originating and development of chronic bronchitis is offered. The scheme of manual treatment these ill is offered and is discussed it efficiency.

Key words: chronic bronchitis, manual treatment.